



Beneficiary Form

Name: MAST ANSH Age: 7 YEARS Sex: MALE DATE: 24-03-2023

Brief details about the Beneficiary: Mast Ansh 7 year old boy suffering from Congenital Heart Defect, s/p VSD Closure+IR+PV. He needs early surgery of sternum wire removal to save his life. There are 5 members in the family and father is the only earning member. He is a farmer. His monthly income is Rs 7,000/-. The treatment is going to be in Max Super Speciality Hospital, under the supervision of Dr. Gaurav Kumar (Senior Consultant Pediatric Cardiology). The total estimate is Rs.1,00,000 /- for the surgery. His family is not in a position to bear the expenses of his treatment.

About the Family:

| | | | | | | | |
|------------------|-----------------|-------------------|-------------------|---------------------|------------------|------------|--------|
| Father's Name | Mr. Sanni Singh | Age | 29 | Edu | 10 TH | Occupation | Farmer |
| Mother's Name | Mrs. Anita Devi | Age | 28 | Edu | 5 TH | Occupation | - |
| Family Member's | 5 Members | No. of Children's | 3 | No. of school going | 2 | | |
| Earning Member's | 1 | Monthly Income | 7,000/- per month | Belongs to | UP | | |



Medical Treatment

| | |
|-----------------------------------|--|
| Hospital/Institution Name: | Max Super Speciality Hospital |
| Address: | Press Enclave Road, Saket, New Delhi- 110017 |
| Diagnosis: | Congenital Heart Defect, s/p VSD Closure+IR+PV |
| Treatment Required: | Sternum wire removal |
| Reg No: | |
| Total (approx.) Treatment/Surgery | 1,00,000/- Rs (ONE LAKH ONLY) |

Reason for which sponsorship required: Surgery: Treatment:

Declaration:

I hereby declare that the information given above is true and I am not in position to afford expenditure expenses.

| | |
|---|---|
|  Signature of Parents/ Guardian |  Dr. Gaurav Kumar MD, DNB (PDS), FNB (Pediatric Cardiology) Senior Consultant-Pediatric Cardiology Max Super Speciality Hospital - East Block (A unit of David Devi Foundation) 2, Press Enclave Road, Saket, New Delhi - 110 017 Regn. No. DMC-5978 Authorized Signatory |
|---|---|

Diya Medicare Foundation is Registered Trust

Donation to Diya Medicare Foundation is eligible for deduction under Section 80 G of the Income Tax Act, 1961.

Date: 24/3/2023

To,


Diya Medicare Foundation

New Delhi

Dear Sir/Madam

This is to certify that Mast. Ansh, 7 years old male, is suffering from congenital heart Defect, s/p VSD Closure+IR+PV. Patient will need sternum Wire removal. The approximate cost of the procedure would be Rs.1 Lac (ONE LAKH ONLY).

The family requires finance assistance from Diya Medicare Foundation for said amount (Rs. 1,00,000 only /-) for the same so kindly help them in all possible way.


Dr. Gaurav Kumar

Sr. Consultant

Pediatric Cardiology

Max Heart and Vascular Institute New Delhi, India


Dr. Gaurav Kumar
MD, DNB (Peds), FNB (Pediatric Cardiology)
Senior Consultant-Pediatric Cardiology
Max Super Speciality Hospital - East Block
(A unit of Devki Devi Foundation)
2, Press Enclave Road, Saket, New Delhi - 110 017
Regn. No. DMC-5978

DEPARTMENT OF PEDIATRIC CARDIOLOGY AND CONGENITAL HEART DISEASES

| | | | |
|------------------------------|-----------|----------------------|------------------|
| Name : ANSH | | Max ID : SKDD.601750 | |
| Age /DOB : 7YRS/M | | DATE : 16.03.2023 | |
| REFERRED BY : FOLLOW UP | | | |
| INDICATION : POST TOF REPAIR | | | |
| Weight: 16.8 KG | SPO2: 98% | HR: 116 BPM | BP : 100/60 MMHG |

FINAL IMPRESSION:

S/P VSD CLOSURE+ INFUNDIBULAR RESECTION+PULMONARY VALVOTOMY DONE IN (11.07.2017)

- PFO SHUNTING LEFT TO RIGHT
- VSD PATCH IN SITU, NO RESIDUAL SHUNT
- RVOT GRADIENT 24 MMHG , FREE PR
- GOOD FLOW SEEN IN BRANCH PAs
- MILD TR
- MILD RV DIASTOLIC DYSFUNCTION
- NORMAL SYSTOLIC FUNCTION

Segmental analysis

| | |
|-------------------------------|---|
| SITUS | : SOLITUS, |
| Cardiac Position | : LEVOCARDIA |
| Atrioventricular connection | : Concordant |
| Ventriculoarterial connection | : concordant |
| VENTRICLES Loop | : D loop |
| Great vessels relation | : Normally related |
| PULMONARY veins | : Normal connection |
| Systemic Veins | : Normal connection |
| Atrial septum | : PFO SHUNTING LEFT TO RIGHT, IAS BULGING TO LEFT |
| Ventricular septum | : VSD PATCH IN SITU, NO RESIDUAL SHUNT |

Max Super Speciality Hospital, Saket

(East Block) - A Unit of Devki Devi Foundation

(Devki Devi Foundation registered under the Societies Registration Act XXI of 1860)

Regd. Office: 2, Press Enclave Road, Saket, New Delhi-110 017

For medical service queries or appointments, call: +91-11 2651 5050

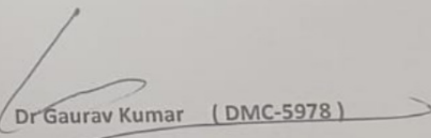
Fax: +91-11-2651 0050

www.maxhealthcare.in

| | |
|---------------------------|---|
| Tricuspid valve | : Mild TR |
| Mitral valve | : NO MR |
| Aortic valve | : NO AR |
| Pulmonary valve | : FREE PR, RVOT GRADIENT 24 MM HG |
| Branch Pulmonary arteries | : GOOD FLOW SEEN IN BRANCH PAs RPA:11MM, LPA:10MM |
| LV/RV SYSTOLIC FUNCTION | : MILD RV DIASTOLIC DYSFUNCTION. TAPSE : 12 MM |
| | LVEF: 58% |
| Diastolic dysfunction | : No IVC congestion |
| Aortic arch | : LEFT ARCH, normal arch branches, NO COA |
| Ductus arteriosus | : No ductal shunt |
| TDI TV SEPTAL | : s' -6.1, e' -7.3, a' -6.7 |
| TDI MV SEPTAL | : s' - 5.4, e' -10.5, a' -4.5 |
| TDI MV LATERAL | : s' -9.2, e' -17.4, a' -4 |

Dr Munesh Tomar (DMC: 31666)

Director

 Dr Gaurav Kumar (DMC-5978)

Senior Consultant

Dr Mamta Malik (DMC: 69382)

Associate Consultant

Dr Subin Manandhar

Fellow